

The effect of honey compared to conventional treatment on healing of radiotherapy-induced skin toxicity in breast cancer patients

Marieke Moolenaar, Robert Louwrens Poorter, Petrus Paulus Gerardus Van Der Toorn, Albert Willem Lenderink, Philip Poortmans & Antonius Cornelis Gerardus Egberts

To cite this article: Marieke Moolenaar, Robert Louwrens Poorter, Petrus Paulus Gerardus Van Der Toorn, Albert Willem Lenderink, Philip Poortmans & Antonius Cornelis Gerardus Egberts (2006) The effect of honey compared to conventional treatment on healing of radiotherapy-induced skin toxicity in breast cancer patients, Acta Oncologica, 45:5, 623-624, DOI: [10.1080/02841860600781799](https://doi.org/10.1080/02841860600781799)

To link to this article: <https://doi.org/10.1080/02841860600781799>



Published online: 08 Jul 2009.



Submit your article to this journal [↗](#)



Article views: 1456



View related articles [↗](#)



Citing articles: 20 View citing articles [↗](#)

LETTER TO THE EDITOR

The effect of honey compared to conventional treatment on healing of radiotherapy-induced skin toxicity in breast cancer patients

MARIEKE MOOLENAAR¹, ROBERT LOUWRENS POORTER²,
PETRUS PAULUS GERARDUS VAN DER TOORN³, ALBERT WILLEM LENDERINK¹,
PHILIP POORTMANS² & ANTONIUS CORNELIS GERARDUS EGBERTS^{1,4}

¹Hospital Pharmacy Midden-Brabant, TweeSteden hospital and St. Elisabeth Hospital, PO Box 90107, 5000 LA, Tilburg, The Netherlands, ²Department of Radiation Oncology, Dr. Bernard Verbeeten Institute, PO Box 90120, 5000 LA Tilburg, The Netherlands, ³Department of Radiation Oncology, Catharina Hospital, PO Box 1350, 5602 ZA Eindhoven, The Netherlands, and ⁴Utrecht University, Utrecht Institute for Pharmaceutical Sciences – Department of Pharmacoepidemiology and Pharmacotherapy, PO Box 80.082, 3508 TB Utrecht, the Netherlands

To the Editor

Although many different treatments have been suggested, no consensus on the preferred treatment for radiation-induced dermatitis has been reached. Medicinal honey is effective and safe in the treatment of various wounds [1]. We initiated a prospective, controlled, randomised study in adult Caucasian females who received radiotherapy to the breast or thoracic wall in daily fractions of 2 Gy over five weeks (total dose of 50 Gy). Patients with grade 3 skin toxicities (RTOG Criteria) larger than 15 mm in diameter, without cutaneous diseases or previous radiotherapy in the region of the skin toxicity, were included. After giving informed consent and randomisation, cases were treated once daily with honey gauze (HoneySoft[®]) and controls with paraffin gauze (Unitulle[®]). Patients were treated until closure of skin toxicity and followed until complete healing (primary endpoint). This was assessed from photographs by a blinded independent physician. Pain, itching, irritation, malodour, and general satisfaction of treatment were measured through daily Visual Analogue Scales (VAS). Differences between treatments were considered statistically significant if $p < 0.05$ (Mann-Whitney Test).

From October 2002 until November 2003, 600 breast cancer patients received radiotherapy of which

27 fulfilled the inclusion criteria (incidence of 4.5%). One patient refused participation and four withdrew during the study. One patient died (honey group, not related to study). Twenty four skin reactions (in 21 patients) were evaluated, of which 12 were treated with honey and 12 with paraffin. The difference in time to complete healing and closure is shown in Figure 1. The VAS results showed a trend towards less pain, itching, irritation in the honey population. No relevant side effects of either skin treatments were noted.

The published incidence of radiation-induced dermatitis grade 3 varies from 10% to 25% [2–5]. The low incidence in this study can be explained by a more selective use of Tissue Equivalent Material (used to increase the dose to the skin and the subcutaneous tissue in the case of high energy photons used for patients at high risk for local recurrences in the skin). Because of the low accrual rate, the need for a high number of patients and the fact that it was not likely to result in a clinically relevant difference in healing time, we decided to close the trial early. Baseline characteristics were reasonably well distributed between treatment groups. In current publications we could not find a study in which one treatment was significantly better for the treatment of radiotherapy-induced dermatitis grade 3 compared to another. A possible explanation

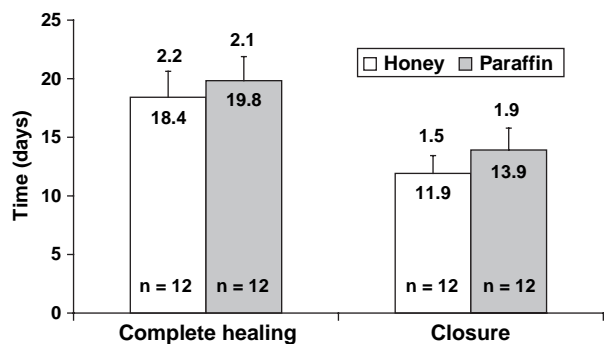


Figure 1. Mean (SEM) time to complete healing (primary endpoint) and closure (secondary endpoint) assessed by the independent physician (days).

for this is the need for large sample sizes to detect small clinical benefits due to high interpatient variation in healing time.

In conclusion, we can state that this study has generated new data on incidence, prognosis, and treatment of acute dermatitis grade 3. Although we could not include enough patients, we found a trend towards faster healing of skin reactions and a greater patient satisfaction with honey than with paraffin. Therefore, the use of honey gauzes can be considered for the treatment of radiotherapy-induced dermatitis.

Acknowledgements

The authors wish to thank the collaborators of the Dr. Bernard Verbeeten Institute for their involvement in the execution of this study. We also express a special note of gratitude to the late T. Postmes, biologist-biochemist, Biomedical Research Foundation, Maastricht, for his stimulating ideas about the use of honey for the treatment of wounds and other medical conditions and his contribution to the first drafts of the research protocol.

References

- [1] Blomfield R. Honey for decubites ulcers. *JAMA* 1973;224:905.
- [2] Bostrom A, Lindman H, Swartling C, Berne B, Bergh J. Potent corticosteroid cream (mometasone furoate) significantly reduces radiation dermatitis: Results from a double-blind, randomized study. *Radiother and Oncol* 2001;59:257–65.
- [3] Lokkevik E, Skovlund E, Reitan J, Hannisdal E, Tanum G. Skin treatment with bepanthen cream versus no cream during radiotherapy. *Acta Oncol* 1996;35:1021–6.
- [4] Maiche A, Grohn P, Maki-Hokkonen H. Effect of chamomile cream and almond ointment on acute radiation skin reaction. *Acta Oncol* 1991;30:395–6.
- [5] Williams M, Burk M, Loprinzi C, et al. Phase III double-blind evaluation of an aloe vera gel as a prophylactic agent for radiation-induced skin toxicity. *Int Radiat Oncol, Biol, Phys* 1996;36:345–9.